

# Unexplained Anterior Uveitis: Viral Causes

KEERTI MUNDEY<sup>1</sup>, ISHFAQ AHMAD SOFI<sup>2</sup>, PRIYA<sup>3</sup>

Sir,

Idiopathic anterior uveitis is increasingly being associated with a viral aetiology. Herpes simplex and Herpes zoster virus (HSV/HZV) are known causes of anterior uveitis but other viruses including Cytomegalovirus (CMV) and Rubella are now being recognized [1].

Viral anterior uveitis has characteristic clinical features, an understanding of which assists the examining ophthalmologist in making an appropriate diagnosis and in initiation of a timely management which varies with the viral strain. The diagnosis may be relatively straight forward in the presence of concomitant skin lesions, active keratitis, and/or corneal anaesthesia. However, in the absence of such clues, the diagnosis requires a high index of clinical suspicion and astute observations, especially as access to intraocular fluid analysis is not available to most clinicians [2].

Herpetic anterior uveitis is characterised by diffusely distributed keratic precipitates (KP), moderate inflammation, posterior synechiae and sectoral or diffuse iris atrophy [Table/Fig-1]. HSV uveitis is suggested by patchy atrophy around the pupillary sphincter [Table/Fig-2] [3]. The intraocular pressure (IOP) is usually raised. HSV usually affects a younger age group whereas HZV is more commonly seen in elderly and immunocompromised patients [4].

Cytomegalovirus (CMV) anterior uveitis has few KPs, mild inflammation with raised intraocular pressure (IOP) and no posterior

**Keywords:** Antiviral therapy, Intraocular fluid, Keratitis

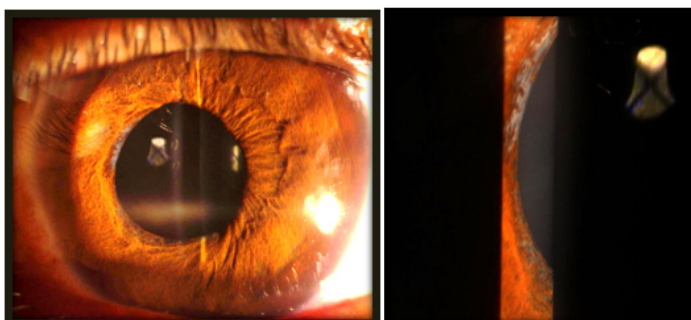
synechiae. The iris has a moth eaten appearance. CMV uveitis can simulate Posner-Schlossman Syndrome, Fuchs' uveitis and herpetic uveitis [5].

Rubella is characterised by posterior subcapsular cataract, mild inflammation, diffuse iris atrophy, lack of posterior synechiae and mildly raised IOP. Fuch's uveitis is now considered to be usually due to Rubella virus. Presence of cataract on presentation is highly suggestive in cases of mild anterior uveitis with raised IOP in a younger age group. In most instances the condition is benign and does not require any anti-inflammatory therapy. An appropriate diagnosis avoids unnecessary work-up and ineffective therapy. Steroids do not have much effect and should be avoided. Follow-up should be regular to monitor lens opacities and intraocular pressure [2].

In summary, in cases of unexplained anterior uveitis, a high index of suspicion regarding possible viral cause should be maintained and antiviral therapy should be considered in eyes with recalcitrant uveitis. As access to intraocular fluid analysis is not available to most clinicians, all attempts should be made to reasonably diagnose the causative virus on the basis of clinical features as a virus specific therapeutic approach is necessary along with standard anti-inflammatory, cycloplegic and antiglaucoma medications.

## REFERENCES

- [1] Kongyai N, Sirirungsi W, Pathanapitoon K, Tananuvat N, Kunavisarut P, Leechanachai P, et al. Viral causes of unexplained anterior uveitis in Thailand. *Eye (Lond)*. 2012;26:529-34.
- [2] Wensing B, Relvas LM, Caspers LE, Valentincic NV, Stunf S, de Groot-Mijnes JD, et al. Comparison of rubella virus- and herpes virus-associated anterior uveitis: clinical manifestations and visual prognosis. *Ophthalmology*. 2011;118:1905-10.
- [3] Huo RS, Coleman AL. Inflammatory glaucoma. In: Singh K, Smiddy WE, Lee AG, editors. *Ophthalmology review: a case study approach*. New York: Thieme; 2002. pp. 93-96.
- [4] Van der Lelij A, Ooijman FM, Kijlstra A, Rothova A. Anterior uveitis with sectoral iris atrophy in the absence of keratitis: a distinct clinical entity among herpetic eye diseases. *Ophthalmology*. 2000;107:1164-70.
- [5] Chee SP, Bacsal K, Jap A, Se-Thoe SY, Cheng CL, Tan BH. Clinical features of cytomegalovirus anterior uveitis in immunocompetent patients. *Am J Ophthalmol*. 2008;145:834-40.



**[Table/Fig-1]:** Diffuse iris atrophic changes atrophy

**[Table/Fig-2]:** Pupillary pigment

### PARTICULARS OF CONTRIBUTORS:

1. Assistant Professor, Department of Ophthalmology, BPS Government Medical College for Women, Khanpur Kalan, Sonapat, Haryana, India.
2. Senior Resident, Department of Ophthalmology, Government Medical College, Srinagar, Jammu and Kashmir, India.
3. MBBS Student, BPS Government Medical College for Women, Khanpur Kalan, Sonapat, Haryana, India.

### NAME, ADDRESS, E-MAIL ID OF THE CORRESPONDING AUTHOR:

Dr. Keerti Munday,  
Assistant Professor, Department of Ophthalmology, BPS Government Medical College for Women,  
Khanpur Kalan, Sonapat, Haryana, India.  
E-mail : keertimannan@rediffmail.com

**FINANCIAL OR OTHER COMPETING INTERESTS:** None.

Date of Submission: **Feb 17, 2015**  
Date of Peer Review: **May 12, 2015**  
Date of Acceptance: **Jun 09, 2015**  
Date of Publishing: **Aug 01, 2015**